



PATIENT

Diana Clements

SPECIES

Feline

BREED

DLH

SEX

Female Spayed

AGE

5 years

WEIGHT

9.5lbs

INTERPRETED BY

Maggie Machen
Lamy, DVM
DACVIM (Cardiology)

IMAGING PERFORMED BY

Pamela Harrigan,
RDCS

HOSPITAL NAME

Mass Veterinary Services

REFERRING VET

Dr. Masloski

INVOICE

27468

DATE

11/15/22

PRESENTING CLINICAL SIGNS

History: Recheck echo. History restrictive/unclassified cardiomyopathy with largely unchanged structural disease on prior echo 5/17/22 (MML). Currently, random spells of wheezing lasting ~ one minute. Good appetite and activity level. On exam: NSR, Grade II/VI parasternal murmur, PSS, lung fields clear, compressible thorax, mm pink, moist. BP: 100mmHg x 5. Current medications: 1) Pimobendan/vetmedin 1.25mg 1 tab twice a day 2) Plavix/clopidogrel 75mg 1/4 tab daily *No sedation for study.
-Pertinent previous echo findings: LA 1.4 cm; LA:Ao 1.7; LV 1.44 cm; IVS 0.3 cm; PW 0.58 cm.; mildly dilated; irregular LV wall thicknesses, thin IVS. VPCs noted previously.

ELECTROCARDIOGRAPHIC FINDINGS *Note: Single lead ECGs are evaluated as a rhythm strip. Morphology/MEA cannot be definitively commented on.

A single lead ECG is available; 25mm/s, 20mm/mV. The average heart rate is 188bpm with a largely regular rhythm. The rhythm is sinus in origin, with a p for every QRS complex and vice versa. P and QRS morphologies are positive. Isolated VPCs are seen throughout. Six in a 1.5-minute tracing; singles only and monomorphic. No APCs, pauses or other dysrhythmias observed.
ECG diagnosis: Normal sinus rhythm with isolated VPCs.

ECHOCARDIOGRAM FINDINGS

2D, m-mode, color flow and Doppler imaging is available.

Left ventricle: The LV diameter is normal with adequate myocardial function. The LV wall thicknesses are irregular with thinning of both the IVS and PW. There is a diffusely hyperechoic endocardium consistent with significant fibrosis. The papillary muscles are mildly remodeled and hyperechoic. The endocardium appears remodeled along the apex.

Left atrium: The left atrium is moderately dilated. No obvious spontaneous contrast or thrombi seen.

Mitral valve: The mitral valve is normal in structure and mobility. Trace central mitral regurgitation. No obvious systolic anterior motion is seen.

Aortic valve/Aorta: The aortic valve is normal in morphology and mobility. Normal aortic outflow velocity; laminar flow. No aortic insufficiency.

Right ventricle: Normal right ventricular diameter and morphology indicating no overt evidence of pulmonary arterial hypertension.

Right atrium: The right atrium is normal in dimension.

Tricuspid valve: The tricuspid valve appears normal with trace tricuspid regurgitation.

Pulmonic valve/Pulmonary artery: The pulmonic valve is normal in morphology and mobility. Trace pulmonic insufficiency. Normal RVOT velocity; laminar flow.

Pericardium/other: No pericardial or pleural effusion noted. No obvious cardiac masses.

2-Dimensional Measurements

Ao diam (cm)	0.8
LA diam (cm)	1.6
LA:Ao (Swe)	2.0
IVS thickness (cm)	0.38
LVID diastole (cm)	1.6
PW thickness (cm)	0.40
LVID systole (cm)	1.0
FS (%)	38

Doppler Measurements

PV Vmax (m/s)	0.74
AoV Vmax (m/s)	1.1
MR Vmax (m/s)	NA
TR Vmax (m/s)	NA
TR PG (mmHg)	NA



PATIENT

Diana Clements

SPECIES

Feline

BREED

DLH

SEX

Female Spayed

AGE

5 years

WEIGHT

9.5lbs

INTERPRETED BY

Maggie Machen
Lamy, DVM
DACVIM (Cardiology)

IMAGING PERFORMED BY

Pamela Harrigan,
RDCS

HOSPITAL NAME

Mass Veterinary Services

REFERRING VET

Dr. Masloski

INVOICE

27468

DATE

11/15/22

INTERPRETATION OF THE FINDINGS

Compared to the prior study, findings are similar. More diffuse thinning is noted, particularly of the posterior wall. Additionally, the LA is slightly increased comparatively. Overall, however systolic function is intact, and no additional issues are identified.

Given these findings, continue medications are recommended. Intermittent wheezing is unlikely to be related to structural disease, given the nature of the episodes. Concurrent respiratory issues should be considered depending on chronicity going forward. Prognosis remains guarded with this degree of atrial dilation, with risk for progression to CHF, development of malignant arrhythmias and/or sudden death going forward.

The ECG shows persistent VPCs with a slight increase compared to the prior evaluation. The abnormal beats remain singles only and monomorphic, suggesting low markers of malignancy. No treatment is indicated at this time.

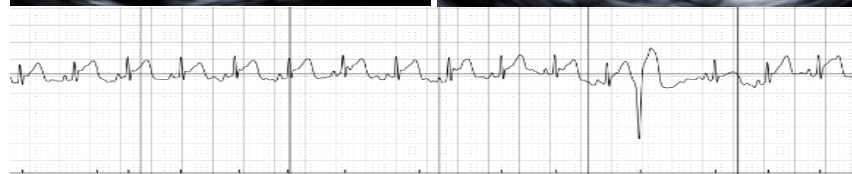
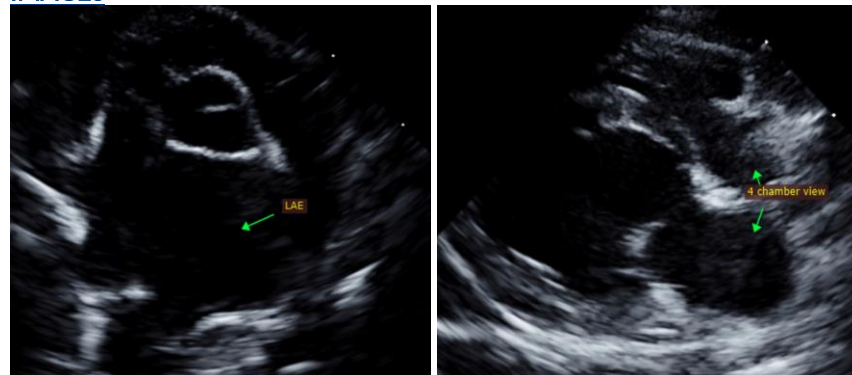
RECOMMENDATIONS

- Continue Pimobendan and Plavix as prescribed.
- Anesthetic risk remains elevated and judicious IV fluid rates should be used to avoid fluid overload. Additionally, drugs that stimulate heart rate should be avoided unless clinically necessary (glycopyrrolate, atropine). Avoid vasodilators as this may worsen the obstruction. A reasonable protocol includes opioid/benzodiazepine premedication, propofol induction, isoflurane maintenance. Additionally, steroids/fluid therapy should be used with caution as there is risk for development of intolerance and fluid retention.
- Monitor for any clinical evidence of cardiac compromise, including respiratory changes and/or signs of a blood clot event (paralysis, neurologic changes, etc.).

PLAN

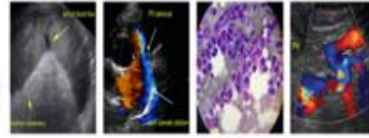
- Recommend recheck echocardiogram and ECG in 6-8 months, sooner if any issues arise in the interim.

IMAGES





Mass Veterinary
Services



SonoPath
Clinical Sonography & Telectyology
EDUCATIONAL TELECONSULTATION SERVICES™
1-800-838-4268 info@sonopath.com SonoPath.com

PATIENT

Diana Clements

The information and recommendations provided are based on the images presented by the referring veterinarian. No evaluation can be communicated regarding pathology that was not visible in the image/video clips provided.

SPECIES

Feline

Thank you for this referral. This report was generated using transcription software, and minor dictation errors may be present. If the clinical or image interpretation does not parallel your findings or if I can be of any further assistance, please contact me.

BREED

DLH

Maggie Machen Lamy, DVM
Diplomate of the American College of Veterinary Internal Medicine (Cardiology)
info@sonopath.com

SEX

Female Spayed

Echocardiogram performed by: Pamela Harrigan, RDCS
Pet Animal Ultrasound Service (4paus.com)

AGE

5 years

WEIGHT

9.5lbs

INTERPRETED BY

Maggie Machen
Lamy, DVM
DACVIM (Cardiology)

**IMAGING
PERFORMED BY**

Pamela Harrigan,
RDCS

HOSPITAL NAME

Mass Veterinary
Services

REFERRING VET

Dr. Masloski

INVOICE

27468

DATE

11/15/22